



with due surgical safety, the risk of infection is minimal.

### References

1. Stephens RP, Richardson AC, Lewin JS. Bilateral subdural hematomas in a newborn infant. *Pediatrics* 1997;99:619-21.
2. Gruber DP, Crone KR. Endoscopic washout: a new technique for treating chronic subdural hematomas in infants. *Pediatr Neurosurg* 1997;27:292-5.

3. Tsutsumi K, Asano T, Shigeno T, Matsui T, Ito S, Nakaguti H. Reduction cranioplasty for a case of intractable chronic subdural hematoma in infancy. *No Shinkei Geka* 1994;22:61-5.
4. Barozzino T, Sgro M, Tbi A, Akouri H, Wilson S, Yeo E, et al. Fetal bilateral subdural haemorrhages. Prenatal diagnosis and spontaneous resolution by time of delivery. *Prenat Diagn* 1998;18:496-503.
5. Romodanov AP, Brodsky YuS. Subdural hematomas in the newborn. Surgical treatment and results. *Surg Neurol* 1987;28:253-8.

Accepted 04.08.2003.

# Recurrent seizures: An unusual manifestation of vitamin B12 deficiency

S. Kumar

Neurology Unit, Department of Neurological Sciences, Christian Medical College Hospital, Vellore - 632004, India.

The present report highlights an unusual presentation of vitamin B12 deficiency— recurrent seizures in a 26-year-old man. His symptoms responded to parenteral vitamin B12 therapy. The relevant literature is reviewed.

**Key Words:** B12 deficiency, Neuropsychiatric manifestations, Seizures.

### Introduction

Vitamin B12 deficiency causing neuropsychiatric manifestations such as peripheral neuropathy, subacute combined degeneration of cord, dementia, ataxia, optic atrophy, psychosis and mood disturbances is well known.<sup>1-3</sup> We report a case with recurrent seizures resulting from vitamin B12 deficiency.

### Case Report

A 26-year-old man presented with recurrent episodes of complex partial seizures of three weeks duration. He had developed behavioral changes one year ago characterized by social withdrawal and memory impairment. Prior to admission, he had neglected self-care, had become severely withdrawn and was disoriented. He was treated with risperidone and carbamazepine.

He had impaired concentration, immediate visual and verbal recall, recent and remote memory, and comprehension for three-step commands. Word output was decreased. He had visuospatial disorientation and constructional apraxia. He had impaired distal sensations, exaggerated deep tendon reflexes except for absent ankle jerks. Plantar reflexes were extensor.

Investigations showed hemoglobin 13.2 g%, reticulocyte count 0.1

%, and mean corpuscular volume 114 fl, hypersegmented polymorphs, and moderate megaloblastic changes on bone marrow. Serum B12 assay was 26 pg/ml and folate was 28 ng/ml. Anti-intrinsic factor antibody was positive. Antral biopsy showed atrophic gastritis. CT scan of the brain showed mild cerebral atrophy. EEG showed left temporal epileptiform activity.

A diagnosis of vitamin B12 deficiency with multiple neuropsychiatric manifestations—dementia, psychosis, seizures, and myeloneuropathy—was considered. He was started on intramuscular vitamin B12 injections with which he showed an excellent therapeutic response. He became independent by the end of the third month. Risperidone and carbamazepine were tapered and stopped by six months. At a follow-up period of 24 months, he had been seizure-free for 23 months and was functionally independent.

### Discussion

Neurological involvement often occurs along with macrocytic anemia but can occur in the absence of anemia or macrocytosis.<sup>2</sup> It is unclear why vitamin B12 deficiency leads to neurological disease in some and hematological disease in others. Methylenetetrahydrofolate reductase (MTHFR) polymorphism has been postulated to protect the vitamin B12-deficient patients against anemia and homozygosity for MTHFR C677T gene could cause the dissociation between hematological and neurological disease seen in some patients with vitamin B12 deficiency.<sup>3</sup>

Methylcobalamin is required in the central nervous system for myelin synthesis. Hence, a lack of cobalamin leads to either the destruction of myelin sheaths or incorporation of abnormal fatty acids in myelin sheaths, thus leading to impaired neural function and/or transmission. This may be the under-



lying cause of neurological symptoms seen in vitamin B 12 deficiency.

The exact mechanism involved in epileptogenesis due to cobalamin deficiency is not clear. It is likely that cerebral neurons with destroyed myelin sheaths are more susceptible to the excitatory effects of glutamate.<sup>4</sup> Cobalamin deficiency may share similarities with multiple sclerosis in this regard.<sup>5</sup>

In conclusion, seizures rarely occur in patients with vitamin B 12 deficiency. Serum B12 levels should be checked, especially in those patients who present with other known neuropsychiatric features of vitamin B12 deficiency. Early withdrawal of antiepileptic drugs should be attempted as long-term antiepileptic use is not warranted and may be associated with adverse effects in such cases. Chronic carbamazepine therapy has been found to lower the levels of vitamin B12 and

folate.<sup>6</sup>

## References

1. Heaton EB, Savage DG, Brust JC, Garrett TJ, Lindenbaum J. Neurologic aspects of cobalamin deficiency. *Medicine (Baltimore)* 1991;70:229-45.
2. Lindenbaum J, Heaton EB, Savage DG, Brust JC, Garrett TJ, Podell ER, et al. Neuropsychiatric disorders caused by cobalamin deficiency in the absence of anemia or macrocytosis. *N Engl J Med* 1988;318:1720-8.
3. Kvittingen EA, Spangen S, Lindemans J, Fowler B. Methionine synthase deficiency without megaloblastic anemia. *Eur J Pediatr* 1997;56:925-30.
4. Akaike A, Tamura Y, Sato Y, Yokota T. Protective effects of a vitamin B12 analog, methylcobalamin, against glutamate cytotoxicity in cultured cortical neurons. *Eur J Pharm* 1993;241:1-6.
5. Poser CM, Brinar VV. Epilepsy and multiple sclerosis. *Epilepsy Behav* 2003;4:6-12.
6. Karabiber H, Sonmezgoz E, Ozerol E, Yakinci C, Otlu B, Yologlu S. Effects of valproate and carbamazepine on serum levels of homocysteine, vitamin B12 and folate. *Brain Dev* 25:113-5

Accepted on 04.06.2003.

# Superior sagittal sinus and torcula thrombosis in minor head injury

**G. S. S. Kumar, A.G. Chacko, M. Joseph**

*Department of Neurological Sciences, Christian Medical College and Hospital, Vellore - 632004, India.*

A 27-year-old man suffered a relatively minor trauma. He developed signs of raised intracranial pressure three days after injury. Investigations revealed superior sagittal sinus and torcular thrombosis.

**Key Words:** Anticoagulation, Superior sagittal sinus, Head injury.

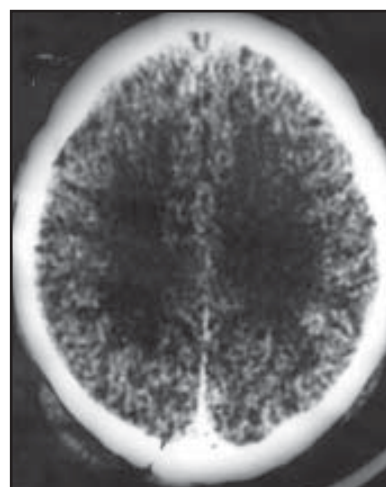
eration was sutured and he was admitted for observation as the fracture line extended across the sagittal sinus. A plain computed tomogram (CT) of the brain showed a crack fracture of the occipital bone on the right side, which extended to the midline. Rest of the brain was normal (Figure 1). Seventy-two hours after the trauma he developed headache and vomiting and developed bilateral sixth cranial

## Introduction

Post-traumatic superior sagittal sinus and torcula thrombosis is rare. Various mechanisms in its pathogenesis have been postulated but mortality and morbidity remain high. We report such a case and discuss the treatment protocol.

## Case Report

A 27-year-old man presented a few hours after a head injury and brief loss of consciousness. When admitted he was irritable but had no focal neurological deficits. There was a scalp laceration in the midline occipital region with an underlying linear fracture. The lac-



**Figure 1:** Plain CT at admission showing fracture of the occipital bone on the right side extending up to the midline. Rest of the brain was normal

**Mathew Joseph**

Department of Neurological sciences, Christian Medical College and Hospital, Vellore - 632004, India.